

LOS ANGELES

COLON AND RECTAL SURGICAL ASSOCIATES

Norman N. Hoffman M.D., Inc.

Gary H. Hoffman M.D.

Eiman Firoozmand M.D.

Liza M. Capiendo M.D.

www.lacolon.com

Anal Fissure

A Pain in the...

(Sorry, we couldn't resist the obvious)

Anal fissures are a common problem, bringing many patients to the colorectal surgeons' office with complaints of anal pain. Most patients report feeling a tear, or a splitting sensation at the anus after a normal bowel movement, a bout of diarrhea, or after a particularly hard or large stool. The discomfort may be mild, or in the extreme, debilitating. Oftentimes, the pain associated with anal fissures is mistaken for hemorrhoidal pain, prompting patients to treat themselves with over-the-counter hemorrhoidal preparations.

Acute anal fissures have the appearance of a simple tear in the anoderm, while chronic fissures, those lasting more than 8-12 weeks, may have an associated sentinel tag distally or a hypertrophied anal papilla proximally. The tag is also called a "sentinel tag" as it is usually located next to the fissure. While acute fissures are superficial and may only involve breaks in the mucosa, chronic fissures may extend to the internal anal sphincter (IAS) and actually expose sphincteric fibers. These may be seen on physical examination (figure 1).

The fissure is located in the posterior midline in 90% of cases. The anterior midline is the second most common location. Laterally located fissures or the

presence of multiple fissures should raise suspicions for possible HIV, Crohn's disease, tuberculosis, or carcinoma.

WHY THE PAIN?

Anorectal trauma secondary to passage of diarrhea or of a hard stool is the most

common cause of an anal fissure. Patients often describe feeling severe pain with bowel movement as if they are "passing glass or razor blades." The pain results from trauma to the numerous sensory nerves that surround the anus. Due to sphincter spasm, pain can linger for several hours after a bowel movement and may feel like a deep-seated

aching discomfort. Rectal bleeding can also present as spotting or as drops of blood in the toilet bowl, turning the water red. The bleeding may be intense, prompting an urgent phone call to the physician, or a visit to the emergency department.

Diagnosis is confirmed on physical exam by gently spreading the buttocks apart. Most times this will elicit discomfort and hypertonia of the sphincter. An anorectal exam will usually reveal a longitudinal line in the anoderm distal to the dentate line with associated internal anal sphincter spasm.

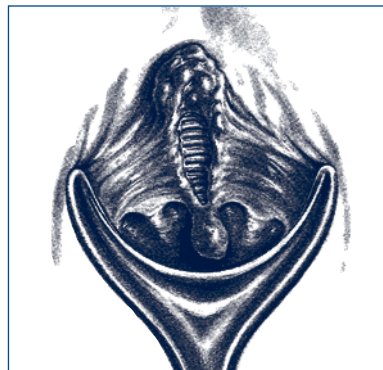


Figure 1. Chronic posterior anal fissure with skin tag and hypertrophied anal papilla. Note fibers of the internal anal sphincter at the base of the wound.

"For a condition with such a small anatomical size, an anal fissure may be associated with an inordinately intense set of symptoms. Treatment is usually both curative and gratifying."

continued on back...

...continued from front

Often, the tear is located in a fold of anoderm and cannot be visualized. Diagnosis and treatment is then based on the clinical history and symptoms. The patient is usually too uncomfortable for an internal examination, and digital exam with proctoscopy can be deferred until the fissure and spasm have resolved. However, coexisting pathology may be present and should not be forgotten or overlooked.

MANAGEMENT...USUALLY A TOPICAL MATTER

Almost half of all fissures heal with conservative therapy involving a high-fiber diet, sitz baths, and emollients. Oral bulking agents are helpful in those patients having hard stools. Although unproven, the use of topical steroidal creams seems to offer immediate relief in the majority of patients. The avoidance of using soap to clean the anal area is important as well. The anoderm is quite sensitive and placing soap on the open wound is akin to placing soap in the eye. It hurts. It can also promote inflammation.

A "chemical sphincterotomy" involves the use of agents designed to reduce resting anal pressures without causing permanent sphincter damage. Nitroglycerin (NTG) 0.2% and Diltiazem® 2% ointments are used topically. The main side effects of these treatments are headache and lightheadedness, mainly seen with NTG. These agents must be made at a compounding pharmacy as the dosages used to treat an anal fissure are different than the standard doses of these medications.

It is thought that nitroglycerin acts as a topical anal sphincter smooth muscle relaxant, enabling an increased blood flow to the injured anal area. The mechanism of action may be similar to its action on the coronary arteries during an episode of angina.

Diltiazim® is a calcium channel blocker and may serve to relax the anal sphincter in the same fashion as during its use in the treatment of hypertension or angina.

Botox® injection into the sphincter has also been used to relieve spasm. A total of 20 units is injected into the intersphincteric groove. The resulting paralysis of the internal sphincter may allow an increased vascular perfusion to the fissure and may facilitate healing. The healing effect lasts for up to six weeks, at which time, a repeat injection may be necessary. The most common side effect is mild incontinence to flatus, and is seen in six per cent of patients. It is a temporary problem, lasting only as long as the effect of the Botox®.

OPERATIVE RELIEF...WHEN ALL ELSE FAILS

Due to non-healing and the continuation of symptoms, it may become necessary to offer operative intervention. Most commonly,

a patient will request an operation as the continued pain is too intense and debilitating.

Increased resting internal anal sphincter pressure with resultant ischemia has been postulated to be the main factor in fissure persistence. Healing is slowed as the vascular supply to the local area is compromised by intense sphincter spasm. Angiographic studies have demonstrated that the posterior anal midline has the lowest tissue perfusion, consistent with the finding that this location is the most common fissure location.

It is important to rule out Crohn's disease as the cause of the tear. Operative intervention in undiagnosed or untreated Crohn's disease may lead to non-healing of the operative site and a worsening of the problem. Likewise, all possible infections should be diagnosed and treated prior to any operative manipulation.

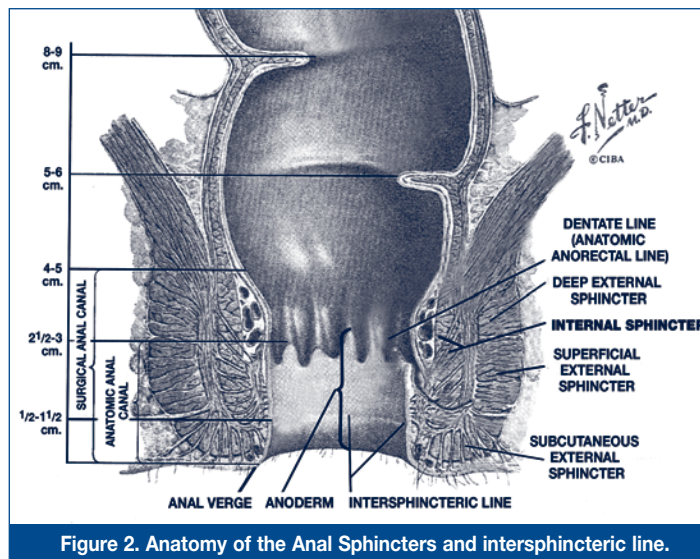


Figure 2. Anatomy of the Anal Sphincters and intersphincteric line.

When symptoms interfere with normal daily functioning, operative intervention in the form of a lateral internal sphincterotomy is offered to the patient. At this point, most patients desire to proceed.

The procedure is performed as an outpatient under intravenous and/or local anesthesia. The intersphincteric groove, between the external and internal anal sphincters is located by palpation (figure 2). A small incision is made over the groove and the leading edge of the internal

sphincter is identified. An incision is made at the leading edge of the muscle and extended proximally for a length approximating the length of the fissure. The mucosa is then reapproximated and the patient is later discharged home. The operation is performed in the lateral location of the anus. Performing the procedure over the fissure itself, usually in the posterior location, is associated with a postoperative deformity known as a keyhole deformity, as the resulting permanent defect looks like a keyhole.

The procedure is safe and associated with a low rate of post operative incontinence; usually less than one per cent at five years postoperatively. Even at that, most patients surveyed reported that the degree of incontinence was minor and did not affect normal daily functioning.

Long term results after a lateral internal sphincterotomy are excellent with respect to pain relief, and the recurrence rate of the fissure is low, less than 4%.

For a condition with such a small anatomical size, an anal fissure may be associated with an inordinately intense set of symptoms. Treatment is usually both curative and gratifying.