

LOS ANGELES

COLON AND RECTAL SURGICAL ASSOCIATES

Norman N. Hoffman M.D., Inc. Gary H. Hoffman M.D. Eiman Firoozmand M.D.
Liza M. Capiendo M.D. Stephen Yoo M.D.

www.lacolon.com

Endorectal Ultrasound Peering Into the Sunless vault

IT IS IMPORTANT TO BE ACCURATE... AND RIGHT.

When it comes to rectal diseases, especially cancer, the treatment, while potentially curative, may be radical, debilitating and exhausting. Any steps that the surgeon can take to lessen the extent of the operative treatment are welcomed by both the patient and the physician. To that end, accurate preoperative diagnosis will allow the surgeon to determine the exact scope of the disease and apply the least radical, yet most effective cure. Therefore, it is important to be accurate... and right.

NEW SURGICAL TECHNIQUES. NEW DIAGNOSTIC MODALITIES.

With the development of pre-surgical, neoadjuvant therapy for rectal cancer, surgeons now have a range of treatment options that minimize morbidity and maximize the potential for cure. With proper use of robotic laparoscopy, and the creation of a neorectum, commonly called a J-pouch, colon and rectal surgeons can minimize morbidity, remove disease and quickly return patients to their normal activities. However, the extent of the rectal disease must be correctly assessed and staged.

Endorectal ultrasound (ERUS) is currently the most widely used and effective diagnostic modality in the assessment of rectal cancer. While its use extends to the diagnosis of other benign conditions such as fistulous

disease, its usefulness in the assessment of rectal cancer location, the cancer's spatial relationship to the anal sphincters, tumor thickness and associated lymph node disease is unmatched. ERUS has allowed surgeons, oncologists and radiotherapists to more accurately plan treatment protocols and carry out surgical extirpations.

THE PHYSICAL EXAM... AND THEN SOME.

Particularly when dealing with rectal cancer, endorectal ultrasound is a crucial component of the workup and evaluation. A tumor's depth of penetration and its nodal status are evaluated, and treatment decisions are made based on the results. Endorectal ultrasound can be performed without anesthesia and is well tolerated in the office or outpatient surgical center settings. Though

recent literature advocates the use of MRI for evaluating the circumferential margins, MRI has not been found to be superior to ERUS when evaluating the precise tumor thickness. The most critical piece of information that is obtained from ERUS is the tumor histological penetration. The tumor size and its distance from anatomical landmarks such as the anal verge and the peritoneal reflection, as well as infiltration into surrounding structures such as the anal sphincter complex are also evaluated. All of this is information that will

continued on back...

Endorectal ultrasound (ERUS) is currently the most widely used and effective diagnostic modality in the assessment of rectal cancer... (It) has allowed surgeons, oncologists and radiotherapists to more accurately plan treatment protocols and carry out surgical extirpations.

Endorectal Ultrasound

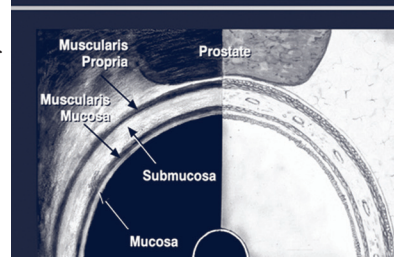


FIGURE 1. An Endorectal Ultrasound View Of Rectal Histology.

COLON AND RECTAL SURGICAL ASSOCIATES

...continued from front

help the clinician determine whether local excision is possible, or whether preoperative chemoradiation is necessary.

TNM.

The TNM system of cancer staging has become a backbone for prognostication. ERUS yields superb evaluation of the T component (tumor thickness) of the TNM system. While not perfect, ERUS also tells much about the possibility of local nodal disease (the N component). The accuracy of ERUS with respect to tumor thickness is in the range of 80% to 90%. For MRI, accuracy rates are between 75% and 85%. The same holds true for the evaluation of nodal disease. ERUS yields nodal detection rates of 70% to 75%, compared with 60% to 70% in MRI.

HOW TO PERFORM ERUS...DON'T TRY THIS AT HOME.

From a preparation standpoint, a patient does not require anesthesia. No special transportation arrangements need to be made. An enema is administered prior to the procedure to evacuate rectal stool and mucus. The procedure takes anywhere from 10-30 minutes to complete. With the patient on the left side, a digital rectal examination is performed, followed by a rigid proctosigmoidoscopy to evaluate the tumor location. The diameter of the ERUS instrument is about 20 millimeters. The probe is advanced and retracted in the vicinity of the tumor to visualize the tumor depth, size, and nearby landmarks. The surrounding fat is also carefully evaluated to assess lymph nodes and possible lymph node involvement. The anal sphincter complex can also be evaluated for tumor involvement. When using ERUS to evaluate benign conditions such as fecal incontinence or fistulas, the sphincter integrity and fistula tracts can be evaluated.

SIZE AND THICKNESS DO MATTER.

The ultrasound probe does an excellent job of evaluating the histological layers of the rectum including the mucosa, submucosa, the muscularis propria and the surrounding fat (FIGURE 1). The images will help the clinician assess which rectal layers are intact or involved by the tumor. The actual staging of colon and rectal cancer is based on the depth of invasion into the distinct histological layers, so precise evaluation does have implications for staging, prognosis and treatment options. At the conclusion of the ERUS, the clinician should have a strong understanding of tumor thickness and any nodal involvement. Combined with other examinations, ERUS results will allow the surgeon to plan, and the patient to prepare.

DOES IT WORK?

Endorectal ultrasound is currently the most effective and widely used diagnostic modality in the overall evaluation of rectal cancer. The accuracy in numerous meta-analyses and trials ranges from 80-95% for T staging and 70-75% for N staging. This is slightly higher than MRI data whose figures range from 75-85% and 60-70% for T and N staging. While reliable, ERUS is least accurate in evaluation of T2 masses, which are often overstaged. However, this over-staging rarely affects treatment planning. A meta-analysis by Steele et al in 2002 evaluated 11 studies and found that the sensitivity and accuracy of ERUS in evaluating T1, T2, T3 and T4 masses was 84%, 76%, 96%, and 76% respectively.

When looking at nodal staging, the accuracy of endorectal ultrasound is specific, but not necessarily sensitive. Metastatic lymph nodes usually are larger than normal lymph nodes. Nodes larger than 3-5mm seen during ultrasound evaluation are considered positive for metastatic infiltration. However, 50% of positive lymph nodes may fall below 5mm, and 8% may be smaller than 2mm. Another study estimated that 18% of nodes less than 5mm could be positive for metastatic infiltration. In addition to size, analyzing hypoechoic patterns results in up to 72% of nodes being correctly diagnosed as having metastatic disease.

Overall, ERUS appears to be slightly superior to MRI in the evaluation of metastatic nodal disease. And, importantly, in all but a few cases of very superficial tumors, all curative operations (a total mesorectal excision, or TME) are performed irrespective of nodal status. Only in patients who have T1 lesions (those lesions extending no deeper than the submucosa) and who refuse, or are unable to undergo a TME, will nodal status possibly influence the extent or type surgical extirpation. So while important in planning radiotherapy and chemotherapeutic protocols, the presence or absence of metastatic nodal disease rarely alters surgical planning.

CAN ERUS DO MORE? OTHER DISEASES.

Other anatomical structures in the pelvis can be seen with endorectal ultrasound. The puborectalis is a muscular hypoechoic band that wraps around the anal canal. The internal anal sphincter also appears as a circumferential band that is external to the surrounding perirectal fat. This vanishes in the lower canal as the hyperechoic external anal sphincter is seen. Seminal vesicles, prostate, bladder and urethra can be evaluated in males, and the vagina, uterus and bladder are also able to be seen in females, albeit less easily.

ERUS is useful in the diagnosis of suspected, but occult perianal or perirectal abscesses. Often, an abscess is suspected but not found during a physical exam. When surgical intervention is contemplated, ERUS (and its cousin EAUS, or endoanal ultrasound) can provide valuable information as to the location and size of an occult abscess. Anal sphincter size and continuity (especially after obstetrical or other trauma) are easily and accurately evaluated by ERUS, and surgical repair may be guided by the ERUS findings. The possible presence of a perirectal fistula, when it is not adequately diagnosed after a physical exam, is a common reason to obtain ERUS confirmation, as the treatment of a fistula may involve the division of a small or larger amount of the anal sphincter. Finally, after the completion of neoadjuvant therapy, but prior to surgery, ERUS can assess the degree of resolution of the rectal mass. Sometimes, therapy causes complete tumor regression and an endoanal ultrasound is helpful in evaluating this phenomenon.

IS ENDORECTAL ULTRASOUND A HELPFUL, IMPORTANT AND SAFE TOOL IN OUR DIAGNOSTIC ARMAMENTARIUM, AND DO COLORECTAL SURGEONS RELY ON THIS EASY, QUICK AND WELL TOLERATED OUTPATIENT OFFICE PROCEDURE?

Yes.