

COLON AND RECTAL SURGICAL ASSOCIATES

Norman N. Hoffman M.D., Inc.

Gary H. Hoffman M.D.

Eiman Firoozmand M.D.

Jeremy Schweitzer M.D.

Liza M. Capiendo M.D.

www.lacrsa.com

January 2006

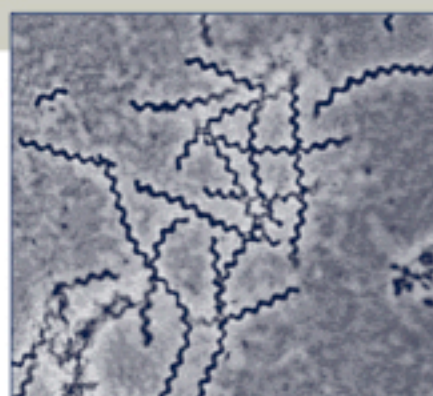
Anorectal Manifestations of Sexually Transmitted Diseases

Common Infections. Many Symptoms.

PART I

The anorectum is a specialized region of the gastrointestinal tract, performing sensory, storage and elimination functions. The mucosal lining in the rectum is columnar. It transitions to a squamous mucosa in the anal canal. It is richly endowed with discriminatory nerve endings to allow the body to distinguish between flatus, liquid and solid waste. While sturdy, the mucosal surfaces are vulnerable to trauma and infections. With or without an anal or rectal injury, sexually transmitted disease may be the source of considerable morbidity. While symptoms may be found in patients with normal immune systems, they are found in increasing frequency in the immunocompromised population. In patients with pre-existing systemic conditions such as AIDS or HIV, common pathogens may take on an even more ominous clinical significance. Part I of this two part article contains a discussion of the anorectal manifestations of the most common sexually transmitted diseases.

"...gonorrhea, chlamydia, syphilis, herpes simplex virus and cytomegalovirus are all part of the differential diagnosis..."



Treponema pallidum.
An ominous Spirochete.

ANAL INFECTIONS

Anal infections are common and the frequency of these infections are increasing. Diagnosis has become more difficult in recent years owing to the complexity of the pathogens. Diagnosis and treatment has become even more challenging in the HIV+ patient population. There are many coexisting variables in the HIV+ population, with the potential for several asymptomatic co-existing infections in the anorectum. These may alter the integrity of the mucosa, thus decreasing the effectiveness of the natural mucosal barrier. Sexually transmitted diseases, such as gonorrhea, chlamydia, syphilis, herpes simplex virus, and cytomegalovirus are all part of the differential diagnosis in the

continued on back...

...continued from front

symptomatic HIV+ patient. Counseling and prolonged follow up is necessary in all patients.

A thorough history accompanied by a focused physical examination will usually yield the cause of an anorectal infection in most patients. Laboratory studies (serological, bacteriological or pathological with tissue biopsy and examination) are confirmatory.

GONORRHEA

Gonorrhea is the most common sexually transmitted infection in the homosexual male. It is caused by *Neisseria Gonorrhoeae*, a Gram negative intracellular diplococcus. It is often seen in conjunction with a chlamydia infection. Symptoms include tenesmus, pruritus and proctitis with a thick yellow mucopurulent discharge. Gram negative intracellular diplococci seen on a Gram stain and subsequently grown on a Thayer-Martin plate confirm the diagnosis. A single, 125mg intramuscular dose of ceftriaxone may be given empirically before culture results are received. Follow up examination with cultures should be performed to confirm the eradication of the disease. Partners should also be evaluated and treated if necessary, as there is increased risk of re-infection from an untreated partner.

CHLAMYDIA

Chlamydia trachomatis is the most commonly reported bacterial sexually transmitted disease in the United States. Chlamydia often coexists with gonorrhea, and treatment should be geared towards both infections. Pain, tenesmus, and proctitis are the typical symptoms. These symptoms often progress to lymphogranuloma venereum, with painful lymphadenopathy, perirectal abscesses and stricture formation. Diagnosis is confirmed by complement fixation testing or urinary polymerase chain reaction tests. Either a single, one gram oral dose of azithromycin, or 100 mg of oral doxycycline taken twice daily for one week are the preferred treatments. However, because of the high relapse rate, many practitioners recommend a two to three week course of doxycycline.

SYPHILIS


Syphilis has often been called "the great imitator", because so many of the signs and symptoms are indistinguishable from those of other diseases. Syphilis is caused by the bacterium *Treponema pallidum*. Anal syphilis manifests as a chancre, or highly infectious ulcer, during the first stage of the disease. Chancres are painless in other sites but cause severe pain in the anal region. The disease progresses to the second-stage, condyloma lata, in one-third of patients. Condyloma lata may appear as smooth painless warts, or raised, red painful

warts and may be accompanied by fever, malaise, and a maculopapular rash on the palms and soles of the feet. Serological diagnosis is confirmed by V.D.R.L. (Venereal Disease Research Laboratory) assay. Initial treatment consists of 1 gram intramuscular benzathine penicillin-LA (long acting). Benzathine penicillin-LA is in short supply and the treatment may need to be changed to doxycycline, 100mg orally, taken twice daily for three weeks. Additionally, the treatment regimen may need to be altered or intensified in the HIV+ patient.

ANAL ULCERS

Herpes Simplex Virus type II is the causative factor in 90% of cases of anal herpes and may be a cofactor in the transmission of HIV by causing breaks in the anorectal epithelial barrier. Cytomegalovirus also causes ulceration and may be a coexisting factor with other anorectal infections. Herpetic ulcers are normally present for ten days. Persistence of herpetic ulcers and vesicles beyond one month is an AIDS-defining condition. Anorectal pain and tenesmus can progress to systemic signs of fever, malaise, and inguinal lymphadenopathy. Biopsy of the ulcer base reveals multinucleated giant cells or intranuclear inclusion bodies. Biopsy sensitivity declines with the progression of healing. Empiric treatment is recommended with 400-800mg of oral acyclovir taken five times daily for one week. Topical acyclovir does not prevent the recurrence of sores, but may decrease pain and itching if applied when the earliest symptoms first appear.

Idiopathic AIDS-related ulcers are usually seen in advanced disease with CD4 T-cell counts less than 200 cells/microliter. These ulcers are differentiated from benign anal fissures in that they occur more proximally and are associated with a hypotonic rather than a hypertonic anal sphincter. AIDS-related ulcers may burrow through the submucosa into the intersphincteric plane, potentially pocketing into the deep post-anal space. This pocketing can cause a sensation of pressure as well as a deep-seated pain. A course of Flagyl and acyclovir may improve symptoms in some patients, but debridement and injection of a depot steroid into the base and sides of the ulcer may be necessary. Often these ulcers are resistant to treatment and can become a considerable source of morbidity. ■



PART II of this article will contain an overview of the Human Papillomavirus (H.P.V.) and its relationship to squamous cell carcinoma of the anus.

Atomic model of the Papillomavirus capsid.